

# Case Report

## An Ovarian Juvenile Granulosa Cell Tumor in Adult

Renuka S\*, Famida A.M\*\*, Vijayalakshmi K\*\*, Sailatha R\*\*\*, Sathiya S\*\*\*

\*Assistant Professor, \*\*Professor, \*\*\*Associate Professor. Department of Obstetrics and Gynaecology, Chettinad Hospital & Research Institute, Chennai, India.



Dr. Renuka S is an undergraduate from Sri Ramachandra Medical College and Research Institute, Chennai. She completed her post graduation (MD) in Obstetrics and Gynaecology from Raja Muthiah Medical College and Research Institute, Annamalai University. She is currently working as Assistant Professor in the Department of Obstetrics and Gynaecology, Chettinad Hospital & Research Institute, Chennai, India.

Corresponding author - Renuka S - ([dralgates@gmail.com](mailto:dralgates@gmail.com))

Chettinad Health City Medical Journal 2016; 5(3): 147 - 149

### Abstract

Granulosa cell tumors (GCT) derive from cells of the sex cord, and produce hormones. In most of the cases they manifest through the symptoms of compressive growth. This case report discusses about a perimenopausal patient, who was hospitalised with lower abdominal pain, without any pressure symptoms and diagnosed to have a large tumor in the abdomen. The tumor was completely removed through staging laparotomy and sent for frozen section, followed by hysterectomy with bilateral salpingectomy and left oophorectomy.

**Key Words:** Granulosa cell tumor, Juvenile, Sex cord tumor

### Introduction

Granulosa cells are somatic cells of the sex cord of the ovary which are closely associated with the developing oocyte. Functions of Granulosa cell is production of sex steroids and varying peptides required for folliculogenesis and ovulation. Granulosa cell tumors (GCT) are derived from granulosa cells. It has an incidence of < 5% of ovarian tumors and > 70% of sex chord stromal tumors<sup>1</sup>.

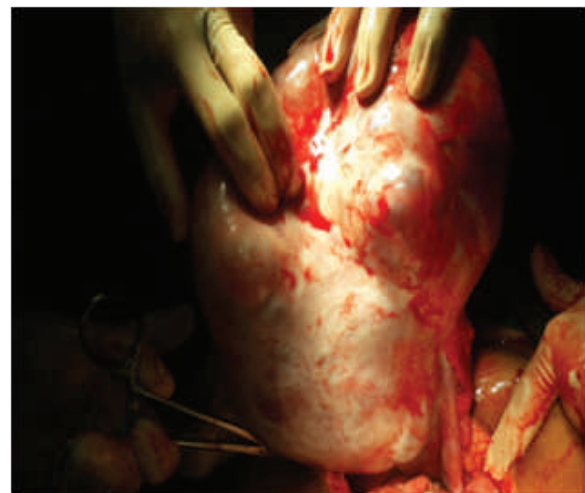Histological types are Adult Granulosa cell tumors, seen in Perimenopausal and postmenopausal women (50 -55 years) and Juvenile Granulosa cell tumors seen in Premenarchal and young girls (5% of all Granulosa cell tumors)<sup>1</sup>.

### Case Report

Mrs Y, 43 Years old Nulligravida was admitted with complaints of spotting per vaginum for 2 months and lower abdominal pain on and off. Patient also gave history of irregular menstrual cycles, which last for 5 days every 40 to 60 days. Her last menstrual periods was 2 months back. On examination, patient's vitals were stable, Per Abdomen-Mass of 32 weeks size, irregular, firm in consistency, associated with tenderness on deep palpation. The lower border could not be made out. Per speculum examination showed healthy cervix and vagina, pin hole os, and bleeding through os. Per vaginal examination revealed a bulky uterus, with fullness of anterior and posterior fornices.

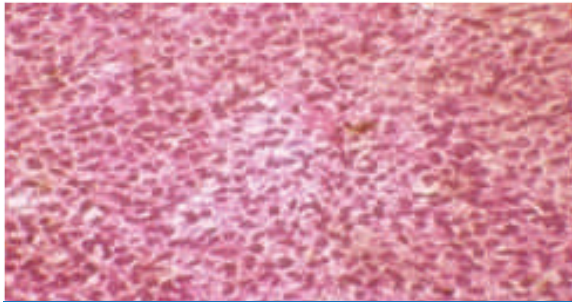
**Laboratory Finding:** Hb - 11.6g /dl, Serum urea-6mg / dl, Serum creatinine - 0.6mg/dl, USG - Right ovary multiloculated cyst present. Endometrial Thickness-12mm, Fractional curettage - No evidence of hyperplasia/malignancy.

**Treatment Given:** Laparotomy was done and proceeded with Total Abdominal Hysterectomy, Right Ovariectomy and Left salpingo-oophorectomy and infracolic omentectomy. Intra operative findings - Right ovarian tumor 20x20cm size, weighing 3 kg, irregular margins with smooth wall and cystic in consistency, capsule intact. (Fig 1). Uterus and cervix normal, No omental deposits or visceral deposits. Nodes not palpable

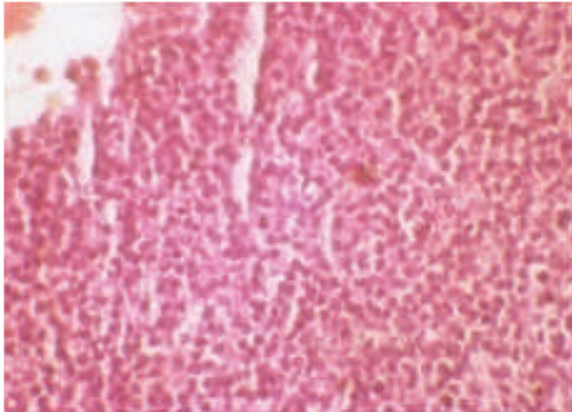


**Fig 1 :** Specimen of Ovarian Cyst

**Histopathology Report** showed Multiloculated mitotically active granulosa cell tumor-right ovary. Nuclear grooving, inconspicuous nucleoli, moderate cytoplasm and extensive luteinisation present. (Fig 2, 3)



**Fig 2 :** Microscopic Appearance of Juvenile Granulosa cell tumor



**Fig 3 :** Mitotic Figure

**Immunohistochemistry** was positive for immunohistochemical stain for inhibin. This is a marker for differentiating sex cord stromal tumors from non sex cord stromal tumors.<sup>2</sup>

**Final Diagnosis** of Malignant juvenile granulosa cell tumor of ovary (FIGO STAGE 1A) was made.

## Discussion

### Juvenile Granulosa Cell Tumor

Usually Granulosa cell tumors (GCT) are unilateral Mass – Tan yellow color due to steroid production. Contains solid and cystic areas. Size of the tumor is > 10 cm in around 73.5% of the cases.<sup>3</sup> Juvenile GCT average around 12.4 cm (5 to 26 cm). Granulosa cells have characteristic coffee bean nuclei. Well differentiated GCT have a microfollicular, macrofollicular trabecular and holotubular pattern. Microfollicular is the most common type and have the characteristic Call – Exner body.<sup>4</sup>

### Microscopic Appearance

Two characteristic distinguishing features of Juvenile from Adult type are<sup>5</sup>

- ▶ Nuclei of Juvenile GCT are rounded , hyperchromatic and grooved with moderate to abundant eosinophilic or vacuolated cytoplasm
- ▶ Theca cell component is luteinized
- ▶ Cuboidal cells with occasional nuclear grooves

FOXL2 gene encodes the transcription factor for the normal development for the granulosa cell and mutation of it is encountered in GCT. The mutation is seen in 97% of Adult GCT and 10% of Juvenile GCT.<sup>6</sup>

## Molecular Genetics

High frequency of mutation suggests pathognomonic for Adult GCT and non appearance of this mutation in Juvenile GCT suggests that these are two different tumors. Granulosa cell proliferation is based on different signal pathways and alteration of these pathways lead to uncontrolled proliferation of these cells resulting in GCT. Pathways involved are Adenyl cyclase / cAMP / Protein Kinase A - activated by FSH on FSH receptor. MAPK and Phosphatidyl inositol 3 kinase pathway - triggered by epidermal growth factor. VEGF and its receptors are involved in angiogenesis.<sup>7</sup>

## Tumor Markers

17B Estradiol, Inhibin, Mullerian inhibiting substance, Follicular Regulating protein.<sup>8</sup>

## Prognostic Factors

Depends on Age, Tumor Size, Rupture of the Tumor, Mitotic Activity, Nuclear Atypia, Aneuploidy, P53 over expression and Stage of the disease<sup>9</sup>

| Stage             | 5 years | 10 years |
|-------------------|---------|----------|
| Early stage (1&2) | 89%     | 89%      |
| Late stage (3&4)  | 72%     | 57%      |

**Survival by Stage – Park et al (1)**

## Treatment

GCT are usually diagnosed by histopathological findings.<sup>4</sup> Clinical Suspicion is based on existence of adnexal mass with features of hyperestrogenism, thickened endometrium and increased serum inhibin. Surgical staging remains to be the initial management of a suspected case of GCT. Postoperatively, treatment with platinum based chemotherapy may be the treatment of choice. This is due to the ease of its administration, wide accessibility and better tolerance.<sup>10</sup> Stage 1 & 2 disease have very good prognosis<sup>1</sup>. Stage 1C disease correlated with poor prognostic factors like large tumor size or high mitotic index have a higher chance of relapse and may benefit with post operative treatment .The efficacy of radiation in GCT is not well defined. Recently, drugs like Tyrosin Kinase inhibitors, Bortezomib, Bevacizumab, may play a greater role in the treatment of GCT.<sup>11</sup>

## Conclusion

Lifelong follow – up of patients diagnosed with GCT is necessary. Follow-up includes clinical examination and tumor markers like inhibin B. This is primarily due to an increased risk of recurrence years after apparent clinical cure of the primary tumor.

## References

- 1) Kottarathil VD, Antony MA, Nair IR, Pavithran K. Recent Advances in Granulosa Cell Tumor Ovary: A Review. Indian J Surg Oncol . 2013; 4 (1): 37 - 7.

- 2) Zhao C, Vinh TN, McManus K, Dabbs D, Barner R, Vang R. Identification of the most sensitive and robust immunohistochemical markers in different categories of ovarian sex cord-stromal tumors. *Am J Surg Pathol*. 2009;33(3):354–66.
- 3) Ranganath R, Sridevi V, Shirley SS, Shantha V. Clinical and pathologic prognostic factors in adult granulosa cell tumors of the ovary. *Int J Gynecol Cancer*. 2008;18(5):929–33
- 4) Lee IH, Choi CH, Hong DG, Song JY, Kim YJ, Kim KT. Clinicopathologic characteristics of granulosa cell tumors of the ovary: a multicenter retrospective study. *J Gynecol Oncol*. 2011;22(3):188 - 95.
- 5) Schumer ST, Cannistra SA . Granulosa cell tumor of the ovary. *J Clin Oncol*.2003;21(6)P:1180 - 9.
- 6) Shah SP, Köbel M, Senz J, Morin RD, Clarke BA, Wiegand KC et al. Mutation of FOXL2 in granulosa-cell tumors of the ovary. *N Engl J Med*. 2009;360:2719–29
- 7) BJamieson S, Fuller PJ. Molecular pathogenesis of granulosa cell tumors of the ovary. *Endocr Rev*. 2012;33(1):109–44.
- 8) Long WQ, Ranchin V, Pautier P, Belville C, Denizot P, Cailla H, et al. Detection of minimal levels of serum anti-Mullerian hormone during follow-up of patients with ovarian granulose cell tumor by means of a highly sensitive enzyme-linked immunosorbent assay. *J Clin Endocrinol Metab*. 2000;85(2):540–4
- 9) Ayhan A, Salman MC, Velipasaoglu M, Sakinci M, Yuce K. Prognostic factors in adult granulosa cell tumors of the ovary: a retrospective analysis of 80 cases. *J Gynecol Oncol*. 2009;20(3):158–63
- 10) Uygun K, Aydiner A, Saip P, Kocak Z, Basaran M, Dincer M, et al. Clinical parameters and treatment results in recurrent granulosa cell tumor of the ovary. *Gynecol Oncol*. 2003; 88(3):400-3
- 11) Gershenson DM, Copeland LJ, Kavanagh JJ, Stringer CA, Saul PB, Wharton JT. Treatment of metastatic stromal tumors of the ovary with cisplatin, doxorubicin, and cyclophosphamide. *Obstet Gynecol*. 1987;70(5):765–9.